

## RCH Trauma Guideline

### Management of traumatic pneumothorax and haemothorax; thoracostomy and chest drain insertion

**See also:**

Major paediatric trauma - [the primary survey](#) and the [secondary survey](#)

[Chest drain management](#)

[Emergency airway management](#)

#### **For children with suspected or confirmed COVID-19**

Given the current low prevalence of COVID-19 in Australia, particularly in children, resuscitation of children, who are not suspected COVID-19, may be as per usual protocols. Where infection is confirmed, or risk is unknown, the following COVID related considerations for traumatic pneumothorax and haemothorax should be adopted. Local policies and procedures should be followed.

- *All staff to don airborne PPE in keeping with local protocols*
- *Most experienced person perform procedure*
- *Double gloves for proceduralist to allow discard of contaminated outer layer*
- *During procedure: observe local COVID related protocols for airway management to minimise aerosolisation*
- *Consider placing a sterile clear plastic drape over patient's chest with the aim that aerosol released with chest decompression travels away from proceduralist*
- *If intubated and ventilated, consider briefly stopping ventilation at the time of blunt entry into the pleural cavity (described next) with the aim of minimising aerosolisation*
- *During pleural decompression: caution must be taken at this stage to minimise uncontrolled leak of air and aerosol*
- *During insertion of chest drain: ensure the intercostal catheter is clamped distally to prevent uncontrolled egress of air/blood once positioned within the thorax*
- *Ensure the clamp placed on distal catheter prior to chest drain insertion is released as soon as the circuit is connected to the underwater drain to allow decompression of pleural cavity*
- *Safely doff PPE as per local protocols*

#### **Key Points**

1. Paediatric patients with traumatic haemo/pneumothorax have sustained a major trauma and are at risk of other serious injuries - all should undergo a comprehensive trauma assessment using [the primary survey](#) and the [secondary survey](#).

2. Management of tension pneumothorax and massive haemothorax with obstructive shock require urgent pleural decompression by thoracostomy.
3. Management of a clinically significant traumatic pneumothorax or haemothorax typically requires pleural decompression by chest drain insertion.
4. Anatomical landmarks should be used to determine the site of incision for pleural decompression within the 'triangle of safety' to reduce risk of harm.
5. All patients in traumatic cardiac arrest who do not respond immediately to airway opening should have both pleural cavities decompressed by thoracostomy, concurrent with efforts to restore the circulating blood volume and optimise oxygenation (see COVID-19 airway CPG for additional precautions required when managing the airway in suspected COVID-19 patients).
6. Following pleural decompression by thoracostomy, a chest drain will ordinarily be inserted as a secondary step prior to leaving the ED as outlined below.
7. Urgent definitive surgical management is indicated in:
  - Massive haemothorax (>20ml/kg blood drains immediately, or >3-4ml/kg/hr thereafter)
  - Massive air leak suggesting bronchopulmonary fistula or air leak compromising ventilationDisposition of these patients should be discussed prior to transfer out of emergency department.
8. Paediatric emergency thoracotomy is not covered by this guideline and practices differ between centres, please refer to local guidelines.

## Background

Blunt chest trauma is far more common than penetrating chest trauma in Australian children.

Clinically significant traumatic haemo/pneumothoraces require pleural decompression. Some traumatic pneumothoraces are not clinically apparent and can be managed safely with observation, especially those first noted on CT. Positive pressure ventilation *per se* is not an absolute indication for presumptive pleural decompression with a chest drain. In the child with traumatic haemothorax it is necessary to decompress the pleural cavity and drain the blood.

With few exceptions, chest drain insertion follows immediately after thoracostomy, with the caveat that the time and place of insertion must be consistent with the child's overall clinical priorities. In the exceptional situation that thoracostomy in ED is **not** immediately followed by drain insertion, it is **imperative** that a clear plan for delayed drain insertion is communicated to relevant staff to ensure this procedure is safely completed at the earliest opportunity.

In trauma obstructive shock can be caused by massive haemo/pneumothorax or cardiac tamponade. A tension pneumothorax or massive haemothorax with obstructive shock should be

empirically treated with urgent thoracostomy; consider investigation and management of cardiac tamponade if limited or no response. This guide does not cover cardiac tamponade.

## Indications for pleural decompression by thoracostomy

1. Tension pneumothorax
2. Massive haemothorax with obstructive shock
3. Traumatic cardiac arrest not responsive to opening airway

## Contraindications

There are no contraindications for thoracostomy which is a life-saving emergent procedure. Risks of relative complications such as coagulopathy are outweighed by the risk of mortality where thoracostomy is required.

## Potential complications

- Recurrent pneumothorax
- Infection
- Iatrogenic organ injury

## Equipment

### For thoracostomy:

- Gloves
- Antiseptic solution using iodine or chlorhexidine skin preparation
- Scalpel blade
- Appropriate sized forceps (see below)

### For chest drain insertion, also:

- Underwater sealed drain system (UWSD)
- Intercostal catheter(s): use smaller sizes for draining air and larger sizes for draining fluid
- Appropriate size sweeping instrument
- Size guide for intercostal catheter insertion in **trauma**

Age group (years)	Suggested sweeping instrument	Chest drain size (Fr)*	Length from drain tip to 4cm mark ** (cm)
0-<2	Mosquito forceps	16	9
2-4	Mosquito forceps	20	10
5-8	Artery forceps	24	12.5

9-12	Artery forceps	28	14
13-16	Clinician's finger/ Roberts forceps	32	14

\* Indicative chest drain sizes are derived from the age-based formula 4× ETT size, and rounded up to the nearest 4 (Fr) in accordance with typical chest drain sizing.

\*\* Length measurements derived from Atrium thoracic catheters, which are in common use in Australasia; exact lengths may vary according to the product used.

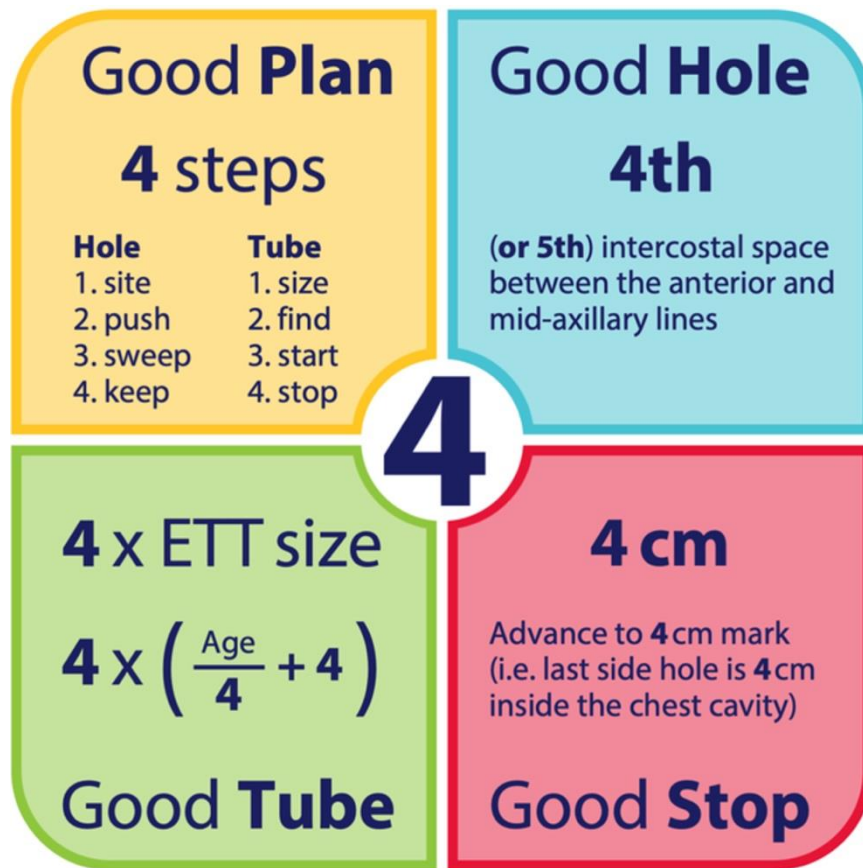
### **Analgesia, Anaesthesia, Sedation**

Thoracostomy is indicated to treat immediately life-threatening conditions. Analgesia should be given quickly without delaying the procedure.

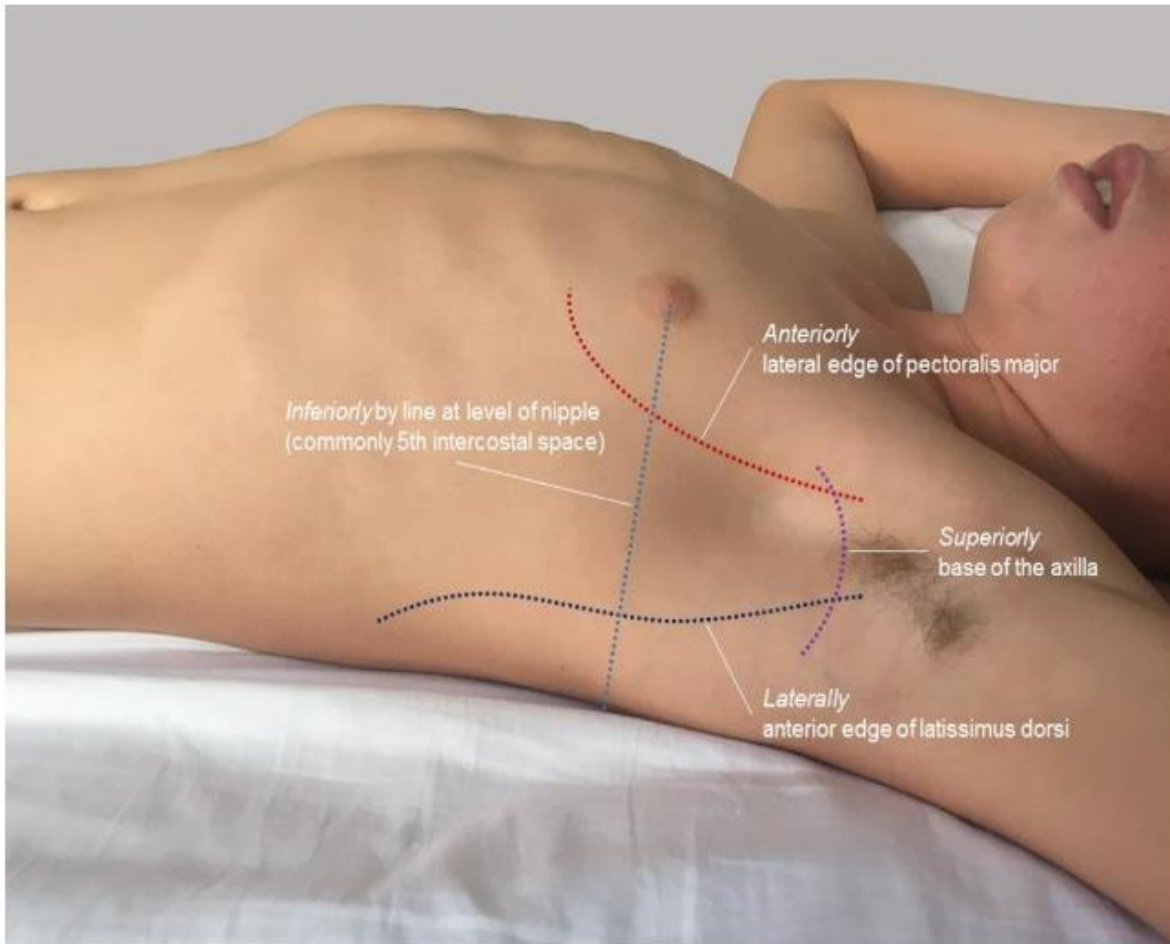
- The use of sedation should always be discussed with a senior doctor, as it can potentially worsen the patient's clinical condition
- Consider procedural sedation (see [Acute pain management](#))
  - **Nitrous oxide should not be used** as it may enter the pleural space by diffusion and rapidly increase the volume of the pneumothorax

### **Procedure: pleural decompression by thoracostomy**

1. Establish patient on continuous cardiac monitoring and pulse oximetry
2. Unless contraindicated oxygen therapy should be administered during the procedure
  - Place trauma patient in head-up, supine position
  - All other patients should be placed in a 45-degree sitting position with the arm that is on the same side as the collection, placed over the forehead
  - ABduct the arms to >90 degrees to locate the triangle of safety
  - Consider use of the rule of 4's for safe and effective pleural decompression and chest drain insertion in trauma



3. Locate the site for incision
- The triangle of safety can be found between:
    - A. Lateral edge of pectoralis major
    - B. Anterior border of latissimus dorsi
    - C. Base of the axilla
    - D. Level of the nipple (typically 5th intercostal space)



4. Briefly prepare the area with surgical skin preparation e.g. alcoholic chlorhexidine or betadine Asepsis is required if a chest drain is inserted to minimise risk of empyema.
5. Using the scalpel blade make an incision on the lateral chest wall between the anterior and mid-axillary lines, parallel to the ribs. The length of this incision will vary with the size of the child and instrument used to dissect for entry into the pleural cavity, e.g. 2-4 cm.
6. Following incision, dissect bluntly with artery forceps (or similar) to enter through the intercostal muscles and pleura. A finger is then introduced into the pleural space to decompress the pleural cavity, allowing evacuation of air and/or blood.
7. Decompression of the pleural and maintenance of the formed tract is optimised by gentle sweeping of a finger or appropriately sized instrument, within the pleural cavity.
8. With few exceptions, chest drain insertion follows immediately after thoracostomy, with the caveat that the time and place of insertion must be consistent with the clinical priorities. The basic steps to perform this are:
  - i. Grasp the proximal tip of the intercostal catheter with a curved clamp, and advance it into the pleural space - aim to guide the catheter posteriorly and superiorly. Do not place the tips of the clamp through the holes of the intercostal catheter.

- ii. Advance the catheter so that the most distal aperture, is 4cm within the thoracic cavity.
  - iii. Anchor the drain and suture the wound. Further secure in place with a waterproof transparent dressing sandwich and anchor the tube to the patient's side.
  - iv. Connect the intercostal catheter to the under water sealed drain (UWSD) and ensure the UWSD is below the level of the patient's chest.
  - v. If the child's status precludes drain insertion in ED a dressing should be applied according to local guidelines.
  - vi. Check for "swinging" of fluid in the connected tube
  - vii. Auscultate the chest for quality of air-entry and observe chest expansion
9. Thoracostomy without inserted chest drain should be accompanied by **intubation and positive pressure ventilation** to ensure adequate ventilation despite air entering the pleural cavity, and reduce the likelihood of re-accumulation of a tension pneumothorax due to entrainment of external air through an open thoracostomy site. Thoracostomy with inserted chest drain may not require intubation with positive pressure ventilation. [See here](#) for emergency airway management including intubation.
10. To reduce the risk of empyema, these children should receive broad spectrum intravenous antibiotic coverage, e.g. **cephazolin** with consideration for metronidazole if soiled.

After the chest drain has been inserted and the air and/or blood drained it is essential to closely monitor the **output** and the **patient**.

### Output

- If a **massive haemothorax** is present (>20ml/kg blood drains immediately, or >3-4ml/kg/hr thereafter), strong consideration should be given to urgent thoracotomy to repair vascular/lung injury and achieve haemorrhage control.
- If a **massive air leak** is present (incessant bubbling of USWD with no swing despite adequate size, functioning drain in the correct place, presence subcutaneous emphysema, reaccumulation of tension pneumothorax despite functioning drain), strong consideration should be given to urgent thoracotomy to repair damaged bronchopulmonary tree and achieve stabilised breathing/ventilation.

**Patient:** if the patient's clinical condition does not improve, or there is deterioration, this may necessitate going to theatre for a thoracotomy.

### Post procedure care

Reassess ABC

Ensure completion of trauma [primary](#) and [secondary survey](#)

- Perform a chest x-ray
- Prescribe further analgesia
- Organise appropriate patient disposition
- If there are concerns of bleeding from the site, or breathing difficulties worsen, that patient must seek urgent medical review

See [chest drain management](#)

## Transfer

All paediatric patients who undergo emergency thoracostomy for traumatic haemo/pneumothorax should be managed at a paediatric trauma centre. Early referral and specialist consultation are recommended.

Emergency advice and paediatric or neonatal ICU transfers, see [Retrieval Services](#).

## References

1. Teague W, Amarakone K, Quinn N. Rule of 4's: Safe and effective pleural decompression and chest drain insertion in severely injured children. *Emergency Medicine Australasia*. 2019; 31:683-687.
2. Quinn, N, Palmer, C, Bernard, S, Noonan, M, Teague, W. Thoracostomy in children with severe trauma: An overview of the paediatric experience in Victoria, Australia. *Emergency Medicine Australasia*. 2019; 32:117-126.