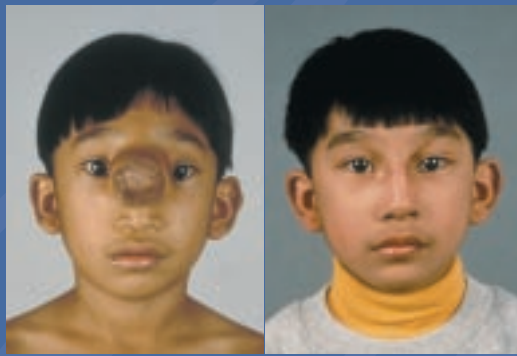

Craniofacial Surgery Information for Patients and Families



The Melbourne Craniofacial Centre
The Royal Children's Hospital



Melbourne Craniofacial Unit

Melbourne Craniofacial Unit

The Melbourne Craniofacial Unit provides complete care and treatment for children with all types of craniofacial disorders. This includes children with birth defects, deformity following accident, or craniofacial growth disorders. Since 1979, our group of highly trained, coordinated specialists has cared for over two thousand patients and their families. This centre of excellence has one of the best safety records for this type of complex surgery.

The craniofacial team

The craniofacial team brings together health professionals from many different fields to ensure that patients and their families receive the best care. The team consists of plastic surgeons, neurosurgeons, oral and maxillofacial surgeons, dentists, ophthalmologists, anaesthetists, geneticists, orthodontists, photographers, orthotists (helmet remodelling), psychiatrists, social workers and specially trained nursing staff, both in theatre and on the wards.

Consultation

On initial referral to the Craniofacial Unit, you and your child will usually be seen in the craniofacial clinic where many of the team members will be present and all aspects of care can be addressed. There is usually a general discussion and some information will be given concerning the likely course of action and possible treatment.

After this initial consultation in the Craniofacial Clinic, you will be referred for specific one-on-one consultation with individual team members as required for ongoing treatment and care. It is during this one-to-one consultation that your specific questions will be discussed in detail. Every team member is committed to getting to know you and your child well during this cooperative experience. Importantly, you will also get to know members of the team and the role each will play in your child's care.

If surgery is recommended, x-rays, scans, and other investigations will be planned as needed. After one of these consultations, it is often advisable to visit the ward where your child will stay. One of the nurses can show you photographs of other similar patients, so that you can be best prepared for the early post operative changes that occur.

What will happen during your child's hospital stay?

If your child is having an extensive procedure admission may be the day prior to surgery.

This will allow you and your child to familiarise with the ward and staff. Anaesthetic checks and pre-operative blood checks can be finalised. For less extensive procedures your child may be admitted on the day of surgery.

Usually there is a single fold-out bed where one parent can sleep beside their child. For patients who come a long distance, further accommodation may be arranged.

On the day of the operation, your child can not have solid food for six hours prior to the procedure. This helps to ensure a safe anaesthetic which is very important. Clear fluids may be given closer to the time of surgery; you will be advised of this by the anaesthetist.

At the time of surgery, you will accompany your child to the pre-operative area. It is important to inform the staff how to contact you during and after the surgery.

We will try to give you an accurate estimate of how long the surgery will take. However, this time is hard to predict and can vary.

When finished, the surgeon will let you know what was accomplished during the procedure and how your child is doing. When your child is awake and settled you will be allowed into the recovery room.

After most craniofacial procedures, your child may have various drips, catheters, arm splints, and bandages in place to help with fluid requirements, pain relief, and other supportive measures.

For a major procedure, your child is usually in hospital for approximately four or five days, however this may vary. After a few days the bandages will be removed and your child's hair can be washed. Significant post-operative swelling can make it difficult for the eyelids to open. This is normal and the children tolerate this well. They can still communicate with their family members and it often only takes two or three days before they can open their eyes. Post-operative pain is easily controlled on the ward with medication. Usually patients can go home when their eyes are open and they are eating and drinking normally.

After discharge

Before going home, you will be given appropriate instructions, and sometimes a moulding or protective helmet will be ordered. Usually you and your child will be seen approximately one week after discharge. Any staples or stitches are easily removed during this visit. It is important during the first six weeks after craniofacial surgery to protect your child from falls and injuries. After six weeks they are usually at no greater risk than any other child. Long term, protective head gear should be worn for contact sports such as football, cycling, skiing, and surfing, just like any normal child.

Follow up is often required after surgery. Once things have stabilized, most children are reviewed annually.

For some conditions a series of operations may be required. This would be determined and explained early in the planning stages. Many patients only require one operation but there is always a chance that further minor adjustments will be needed.

Craniofacial anatomy and growth

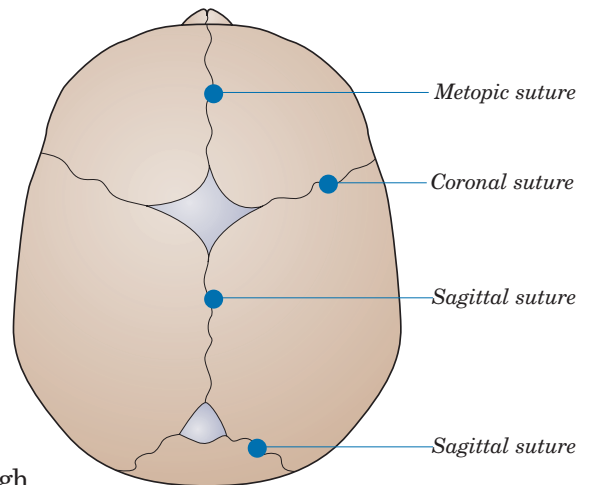
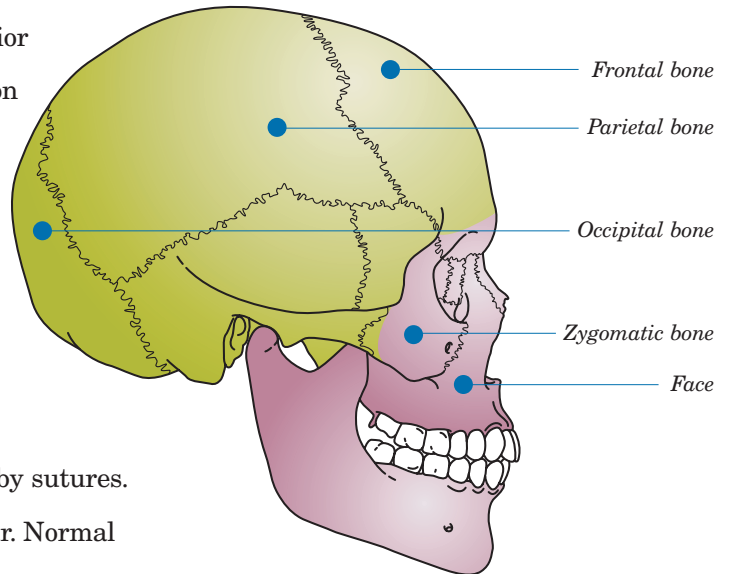
The human head contains numerous bones surrounding the brain; together these bones are called the skull (or cranium). The bones

of the face are suspended from the anterior portion of the cranium. This bony skeleton is responsible for the shape and form of the face and head. Abnormalities of this underlying bony skeleton lead to craniofacial problems and correction of these deformities is the object of craniofacial surgery.

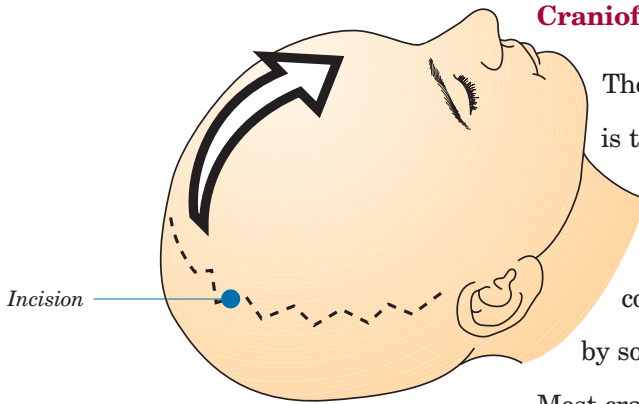
The bones of the cranium are separated by sutures. These sutures allow early growth to occur. Normal sutures in a developing baby are quite wide with a large separation between the bones. This allows the rapidly growing brain to expand without restriction, displacing the cranial bones outwards. Most of the growth of the brain and the skull has occurred by the age of two, with periods of rapid growth during the first nine months of life.

As the growth of the brain approaches completion the bony plates fuse together.

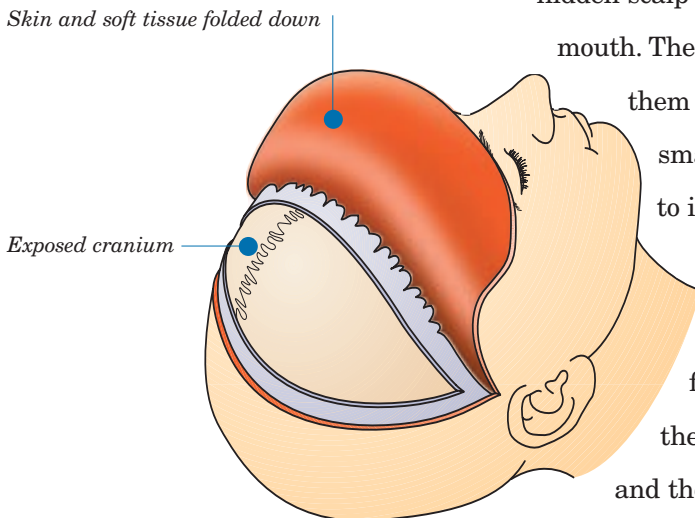
The facial bones develop in a similar fashion, although the time of rapid growth is in the teenage years. It is for this reason that many operations on the facial bones are delayed until later in puberty when most of the growth is complete, whereas cranial deformities are often corrected in infancy.



Craniofacial surgery



The guiding principle of craniofacial surgery is that the bony skeleton is the foundation for appearance, structure, and function of the craniofacial region. Therefore, skeletal correction is usually performed first, followed by soft-tissue reconstruction.

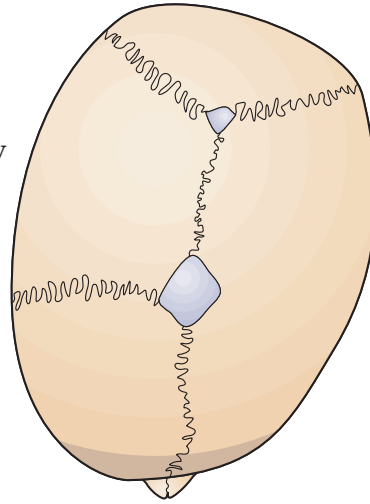


Most craniofacial operations are performed through hidden scalp incisions within the hairline, or within the mouth. The incisions may be curved or wavy to make them less detectable in the long term. Only a small amount of hair is usually shaved prior to incision.

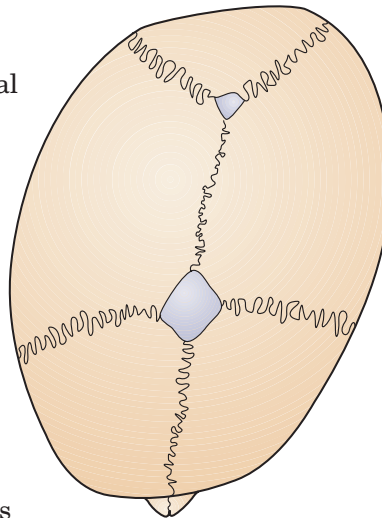
Through scalp incisions, the skin and soft tissues including the muscles of the face, can be safely folded down to expose the bones. These bones can then be reshaped and the brain protected. The fused sutures can be excised, allowing the growing brain to shape the cranium and deformed bones can be remodelled and replaced in their normal position. The bones are held in position by fine wires and sometimes plates and screws, some of which are dissolvable. The skin and soft tissues can then be re-draped over the bony skeleton and held in their normal position.

Abnormal head shape

There are many different descriptive terms for a wide variety of craniofacial problems. However, the most common deformity seen today is called plagiocephaly, literally 'crooked head'. This is most often a deformational process perhaps caused by intra-uterine compression (before birth) and continued by laying a child on the same side after birth. It is therefore often called 'deformational plagiocephaly'. This is generally a problem that can be corrected by changing the way the child is positioned during sleep. A moulding helmet may be helpful for some children. Deformational plagiocephaly can be distinguished from a less common form of 'synostotic plagiocephaly' by physical examination. Synostosis is caused by premature fusion of the sutures between the bones of the skull. Skull x-rays and CT scans may be required to differentiate synostotic from deformational plagiocephaly. The distinction is important, because synostosis requires surgical correction.



Synostotic plagiocephaly—note closed coronal suture.

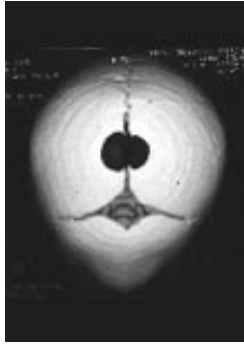


Deformational plagiocephaly—note the 'crooked head' but all the bone sutures are open.

Nonsyndromic craniosynostosis




Metopic synostosis




CT of metopic synostosis

The sutures between the bones of the skull sometimes close or fuse prematurely. When this occurs it results in a deformity in the shape of the skull, which may get worse as the skull grows during the first two years of life. This is termed synostosis (or craniosynostosis). Normally the two frontal bones are separated by the metopic suture, the two parietal bones by the sagittal suture, the coronal suture lies between the frontal and parietal bones, and the lambdoid suture between the occipital and parietal bones.

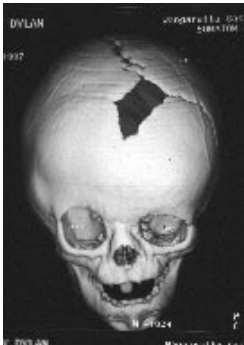

Patient age 3 and 21 after infant correction

The particular deformity and resultant shape of the head is determined by which suture has prematurely fused. If the metopic suture fuses between the frontal bones, the forehead develops a triangular shape with a prominent 'keel'. There is a recession of the region lateral to the eyes (temples) with a decreased distance between the eyes (hypotelorism). The resultant head shape is termed trigonocephaly.



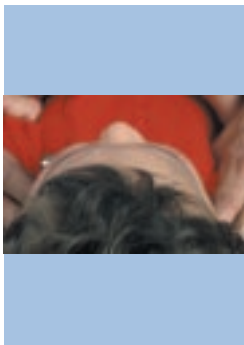
Plagiocephaly




CT of plagiocephaly



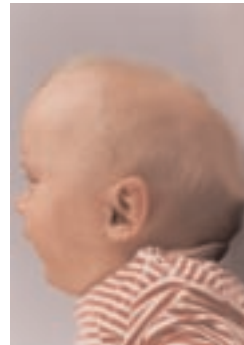2 years after surgery



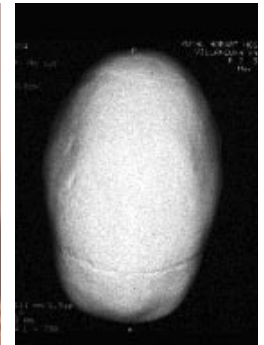12 years after surgery



If one of the coronal sutures between the frontal and parietal bones fuse then the resultant head shape is called plagiocephaly and consists of a flattening of the forehead on that side, a bulge posteriorly, a widening of the bony orbit, and malposition to the nose and chin. As mentioned above this needs to be carefully distinguished from deformational plagiocephaly.

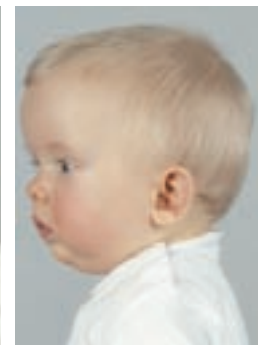

Sagittal synostosis



CT of sagittal synostosis

If the sagittal suture between the two parietal bones becomes fused, growth is restricted from side to side and the growing brain pushes forward and backwards, producing an elongated head shape known as scaphocephaly.

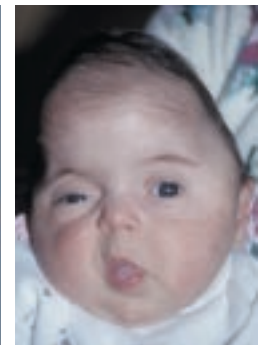
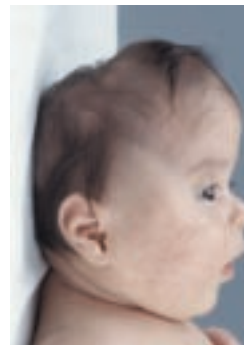

Sagittal synostosis 6 months after surgery

If both coronal sutures are fused, the length of the skull from front to back is reduced and there is a compensatory widening to give a short, squarish head which is termed brachycephaly.

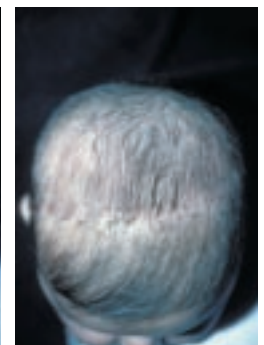
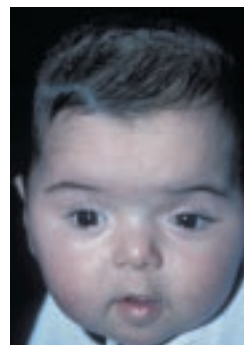If one of the lambdoid sutures is fused, the changes are similar to plagiocephaly but more pronounced at the back of the skull.

More than one suture may be fused, although this usually occurs within the setting of one of the craniofacial syndromes described later.



Cloverleaf deformity

When multiple sutures are fused, the shape of the head often resembles a cloverleaf and this has been termed cloverleaf skull or Kleeblattschadel deformity. This is very serious because brain growth will be restricted.



Cloverleaf deformity 8 weeks after surgery

Syndromic Synostoses

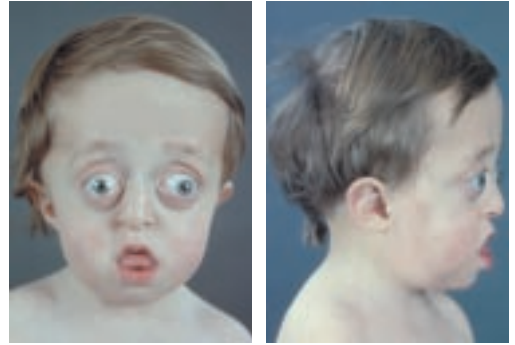
There are over 200 craniofacial syndromes. These syndromes feature premature fusion of the skull associated with an abnormal gene. Therefore, syndromes often run in families. Affected children may have other features of abnormal head and facial growth, as well as peripheral orthopaedic disorders. The common craniofacial syndromes are Crouzon, Apert, Pfeiffer, and Saethre Chotzen syndrome.

Recent laboratory studies have revealed that there are alterations in the molecular structure of particular genes which are responsible for producing protein molecules called fibroblast growth factor receptors. The role of these genes and proteins is currently being investigated in many centres throughout the world, including ours, and may lead to a better understanding of these conditions as well as potential for prenatal diagnoses in selected patients.

These genetic changes can lead to a wide range of anomalies in tissues and organs apart from the craniofacial skeleton. Genetic counselling forms an important part in the management of families affected by these conditions.

Crouzon Syndrome

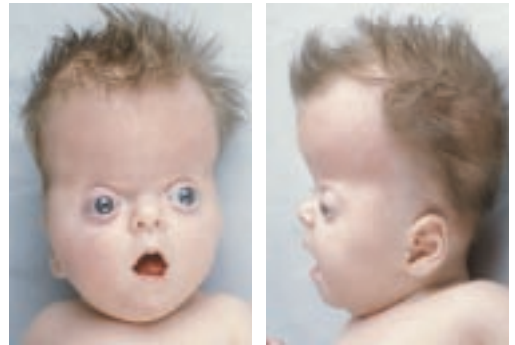Crouzon syndrome consists of coronal suture fusion on both sides, producing a short, wide head (brachycephaly) in combination with under development of the middle of the face, including the upper jaw. This can result in small eye sockets, leading to prominent eyes and the infant can have difficulty closing its eyelids.



Crouzon syndrome

Apert Syndrome

In Apert syndrome there is also coronal suture fusion leading to brachycephaly as well as poor development of the middle of the face and upper jaw. The skull is a little different than with Crouzon, tending to be of a larger size, with a very prominent forehead which may grow upward in a tower-like fashion (turricephaly).

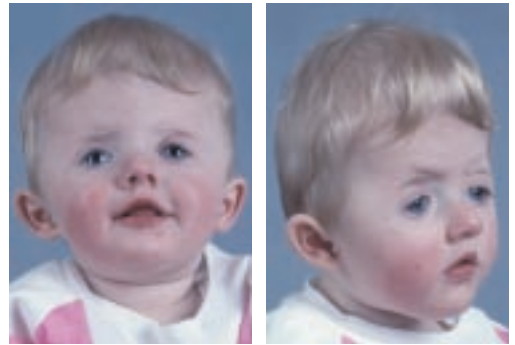

Apert syndrome

In addition, patients with Apert syndrome have severe complex webbing of the fingers and toes, which is called syndactyly. They may have anomalies of the brain as well as an abnormal drainage of fluid around the brain (hydrocephalus).

Pfeiffer Syndrome

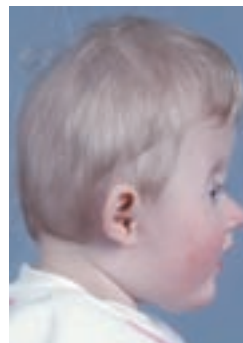Pfeiffer's syndrome consists of brachycephaly due to coronal synostosis in association with broad thumbs and great toes.



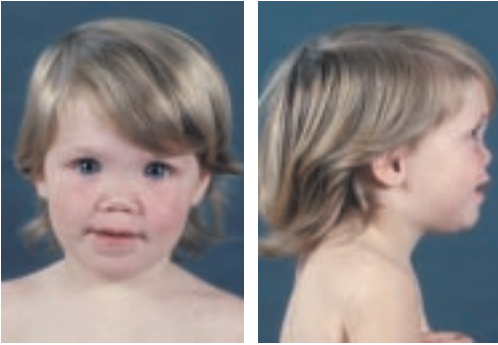Saethre Chotzen syndrome

Saethre Chotzen syndrome

These patients have coronal suture fusion with brachycephaly as well as a prominent forehead, low hairline and bilateral drooping (ptosis) of the upper eyelids. They may have slightly short fingers and toes with mild webbing between their fingers.



Disorders of growth



Binder syndrome



Binder syndrome with temporary nasal enlargement



Binder syndrome – 20 year follow up after nasal reconstruction and advancement of the mid face

There are many disorders of growth that can result in over or underdevelopment of the facial bones and jaws. These can all be improved with craniofacial surgery. Binder syndrome and fibrous dysplasia are typical examples of these disorders.

Binder Syndrome

Binder Syndrome is characterised by a deficiency in growth of the mid-face between the mouth and brow. This results in children who have a poorly developed nose and poor jaw alignment. Treatment for this condition usually includes orthodontics as well orthognathic surgery to reposition the jaw to allow the upper and lower teeth to meet together.

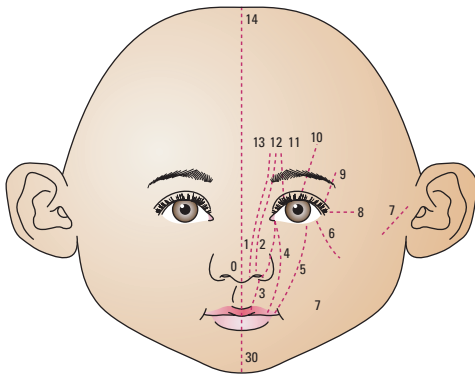
Once the midface has been placed in the proper position with this surgery, attention can be directed towards the nose, which can be supported and enlarged with a bone graft.

In very severe cases, the nasal skin can be stretched from an early age with artificial implants. In this manner, an excellent early facial appearance can be achieved which can prevent teasing at school. These procedures usually begin after the eruption of the secondary teeth, at approximately 7–11 years of age, but final surgery is often not completed until growth is finished.

Fibrous dysplasia

Fibrous dysplasia is one of several over-growth syndromes. It is a generally a benign disease of bone that is characterized by the replacement of normal bone with tissue similar to scar (fibrous tissue).

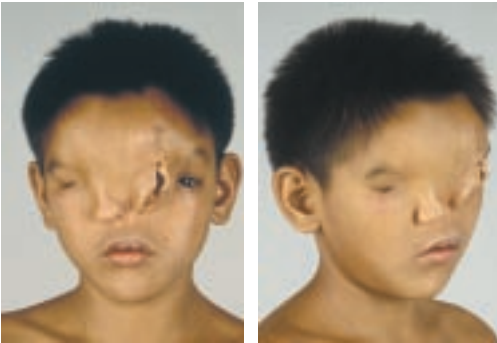It can involve one or more sites and is typically noted at around 10 years of age. It can present as simple facial swelling, and can progress to gross asymmetry with over-growth of the craniofacial skeleton. Surgery can be performed to remodel this overgrowth or even to prevent blindness.



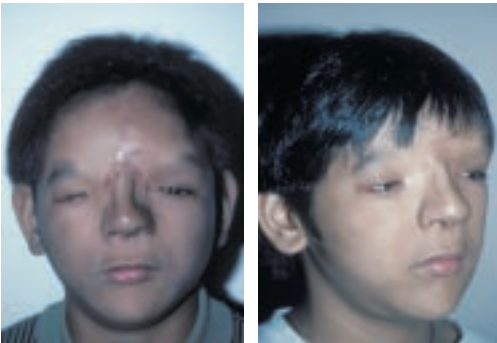
Clefting disorders

Tessier Clefts

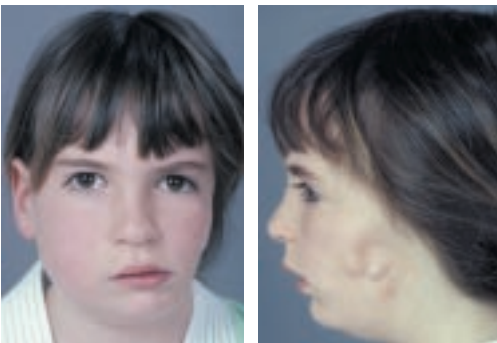Rarely facial clefting may occur which is more extensive than the more common cleft lip and palate. These clefts are of varying severity from minor areas of hair loss or notching to complete clefts in the skin and bone. They are classified according to the ‘Tessier Clock’ as illustrated. Usually excellent results can be achieved with craniofacial surgical correction.



Rare Tessier Clefts involving upperjaw, nose and skull



Tessier Cleft patient after reconstruction



Craniofacial microsomia

Craniofacial microsomia

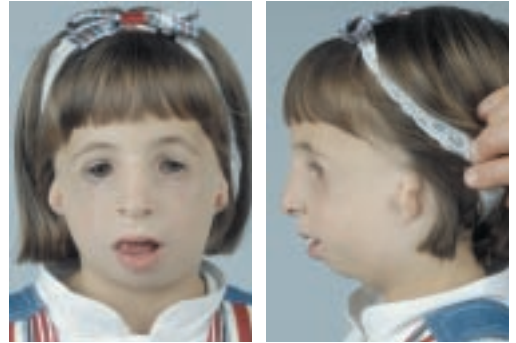Craniofacial microsomia entails a lack of development of one or both sides of the face.

It has many names including hemifacial microsomia and Goldenhar syndrome. This condition has a wide range of manifestations. In mild cases patients have one sided facial underdevelopment with skin tags in front of their ears. Severely effected patients sometimes have a profoundly affected, small jaw and are missing an ear.

As it is a variable condition, some patients are very mild and require no active treatment, while others require orthodontics and jaw surgery to improve the way the teeth meet (occlusion) and facial symmetry. Craniofacial surgery and tissue transfers to improve the facial appearance are needed for severe cases and often construction of an entire ear is needed.

Treacher Collins

Treacher Collins syndrome is a genetic disorder of facial growth on both sides. It consists of abnormal jaw growth, with clefts in cheek bones and lower eyelids. Ear malformations are seen, and patients are often deaf. Good results can be achieved with craniofacial surgery and hearing aids can be fashioned around artificial or constructed ears.



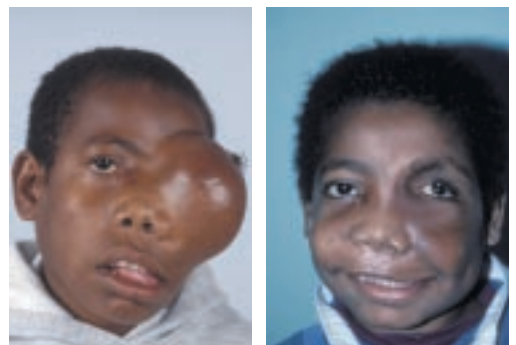Treacher Collins syndrome

Trauma

Major injuries to the face and skull can now be successfully treated with craniofacial surgery techniques. Trauma can include damage to the soft tissues of the eyelids, lips, nose and cheeks as well as to the bony structures. Craniofacial principles are applied in order to rebuild the facial skeleton, limit scars and improve function.

Tumours

Occasionally young children with tumours are brought to the attention of the craniofacial team. If cancerous, these tumours are managed in combination with the Oncology Unit. Benign tumours can often be treated with simple surgery alone with excellent cosmetic results. Some of the aggressive tumours can be cured with a combination of pre-operative chemotherapy, surgical excision of the area, and accurate reconstruction of the craniofacial skeleton and soft tissues to produce a healthy, normal-looking child.



Tumour resection and reconstruction



Encephalocele



Encephalocele after surgery



Encephalocele



Encephalocele after surgery

Encephalocele

An encephalocele results from failure in formation of the structures covering the brain in the embryo leading to a hernia or outpouching of brain tissue through a hole in the skull. Encephaloceles commonly present between the eyes at the top of the nose. They can also be found in other positions on the skull. There are often associated changes in the shape of the skull and eye sockets. The nose is often severely deformed.

Craniofacial principles apply to the correction of these deformities with a wide exposure through the incision across the top of the head. A direct incision over the protruding encephalocele is frequently needed. The lining around the brain is dissected and the contents reduced back into the skull and the lining repaired. The cranial bones surrounding the defect may then need to be removed, reshaped or replaced with bone grafts. Excess skin may then need to be excised or rearranged.

Conclusion

The Melbourne Craniofacial Unit based at the Royal Children's Hospital in Melbourne draws together the expertise of world-class specialists.

- The aim is to help families and children with craniofacial disorders due to congenital problems (present at birth), damage from trauma, or tumours.
- Our aim is to provide integrated complete care for patients and their families, enabling the children to achieve their full potential in life.
- If you have any questions please feel free to contact our craniofacial co-ordinator
telephone 03 9345 6582
facsimile 03 9345 4649
email cleftcraniofacial.service@rch.org.au
www.rch.org.au/plastic