

microtia & ear anomalies in children



Department of Plastic and Maxillofacial Surgery
The Royal Children's Hospital, Melbourne, Australia

microtia & ear anomalies

in children

The Department of Plastic and Maxillofacial Surgery provides comprehensive care to children with a wide range of birth defects and deformities after accidents. Since 1970, our group of highly trained and specialized surgeons has cared for thousands of patients and their families. Our microtia team aim to provide world leading care for patients with congenital or accident related deformities of the ear and is one of a handful of clinics worldwide to provide such a service.

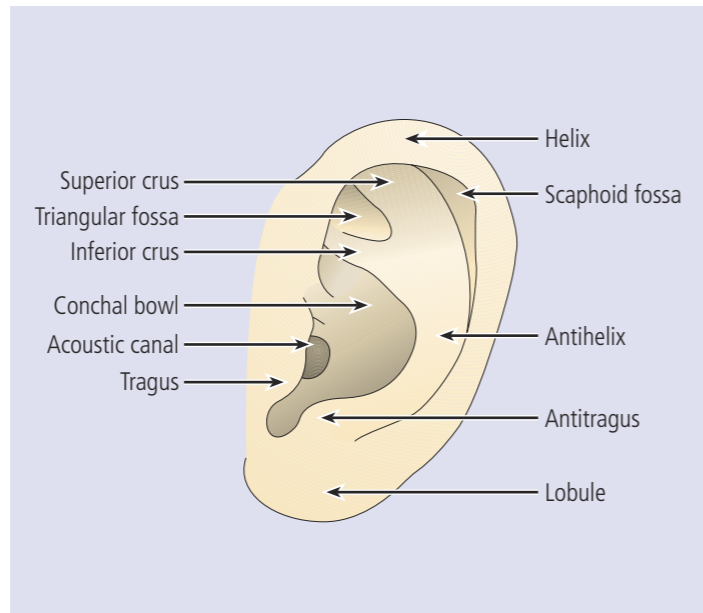
This booklet was prepared by Mr Nicholas Lotz FRACS, craniofacial fellow, in conjunction with plastic surgeons Mr Chris Coombs FRACS and Mr Andrew Greensmith FRACS, and ENT surgeons Mr Rob Briggs FRACS and Mr Markus Dahm FRACS.

Microtia and related ear anomalies

Anatomy

Figure 1 shows the normal anatomy of the external ear.

Figure 1. Normal anatomy of external ear



Embryology (development) of the ear

The formation of the ear occurs during the first trimester of pregnancy. It arises from six lumps of tissue called "hillocks" on the side of the embryo's head. These then develop into the various parts of the external ear.

A child's ear reaches 95% of adult size by the age of six.

What is microtia?

Microtia is an incomplete or abnormally formed ear. It literally comes from the words "micro" (small) and "otia" (ear). Microtia may affect one side only (unilateral) or affect both ears (bilateral). Eighty percent of the time it is unilateral.

Some people may have microtia as part of a syndrome known as craniofacial (or hemifacial) microsomia. In this condition, there may also be a small jaw and weakness of some of the facial muscles on the affected side. Treacher Collins syndrome, in which the eyes and facial bones are affected, is also another rare condition that may be associated with microtia. Pictures 1–3 show different forms of microtia.

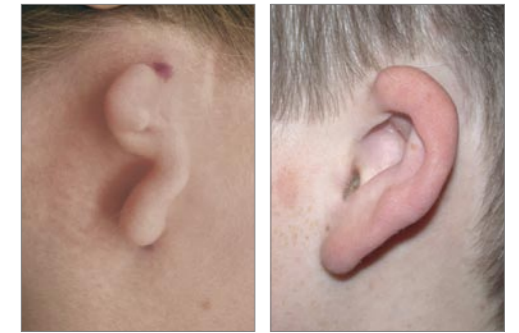
How common is microtia?

Microtia occurs in around 1 in 6000 births. The chance of an affected parent transmitting this to their children is usually small (less than 6%), but there are some families who carry a gene for microtia.

What causes microtia?

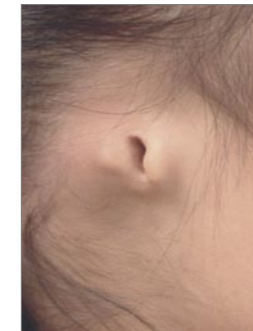Microtia occurs when there is a problem with the development of the ear in the embryo. The deformity is thought to be due to an abnormality of the blood vessel supplying the area around the ear in the embryo. This is still uncertain, and nobody knows what causes this to happen. Occasionally it is due to an inherited defect, but more often it is a one-off condition that the child with microtia will not pass on to their own children.

There is no evidence that anything a mother does during pregnancy causes microtia.



Picture 1. Lobular type microtia

Picture 2. Microtia affecting upper part of the ear only



Picture 3. Anotia – absence of the entire ear

Is the hearing affected?

In some cases of microtia the hearing may be normal or partly reduced and not require any treatment. Patients with microtia may not have an external ear canal, but this does not necessarily mean that they cannot hear on that side, as the inner ear may be normal. In others, there may be problems with the formation of the middle ear which can affect hearing.

Children with unilateral microtia with absence of the ear canal on that side will often have problems identifying which direction a sound is coming from.

Your child will need to have audiograms to test their hearing, and also a CT scan to look at the small bones in the middle ear to determine whether or not hearing can be improved in the ear.

The CT scan is also used to determine the position of the facial nerve as it passes through the middle ear. The position of the facial nerve in the middle ear can also determine if it is possible to reconstruct an ear canal on the affected side. As any surgery to restore hearing is usually done after reconstruction of the external ear, a CT scan is often not done until after seven years of age at which time they may not require a general anaesthetic for the scan.

Who treats microtia?

It is important that microtia and other ear deformities are treated by surgeons specializing in these conditions to ensure the best chance of a good result. The treatment of microtia needs to address the functional problems (hearing loss) as well as the aesthetic concerns (how the ear looks).

Not all children with microtia will have problems with their hearing. Your child will be seen in a special clinic by doctors and health professionals from the following areas:

- Plastic surgeons, who are involved with making a new external ear.
- ENT (ear, nose and throat) surgeons, who are involved with restoring or improving hearing to the affected ear (if needed).
- Craniofacial surgeons if the jaw or other bones of the face are involved (in cases of craniofacial microsomia).
- Geneticists who can advise you further on the possibility of future children being affected.
- Other services that your child at The Royal Children's Hospital may require will also be organized through the microtia clinic.

What surgery is involved?

To create a new ear, the choices are either to use tissue from the patient's own body (autogenous reconstruction), to use synthetic materials (alloplastic reconstruction), or a combination of the two.

Autogenous reconstruction involves making a new ear from the patient's rib cartilage which is then placed under the skin on the side of the scalp where the ear should have been. The ear lobe that is usually present is repositioned into its normal position. A second operation is required to lift the ear out from the side of the head and create the groove behind the ear with a skin graft.

An alloplastic reconstruction can involve either a plastic clip-on ear (osseointegrated prosthesis), which attaches to surgically placed studs in the bone on the side of the head, or the use of a material called Medpor (porous polyethylene), which is placed under the skin in a similar manner to the rib cartilage in an autogenous reconstruction.

Sometimes your child may require surgery to pin back the other ear to more closely match the reconstructed one.

Is an autogenous reconstruction or an alloplastic one better?

The answer is probably an autogenous reconstruction using the patient's own rib, but in some cases an alloplastic reconstruction may be preferred.

The advantage of an autogenous ear reconstruction is that it is more resistant to trauma, and hence can be treated more like a normal ear after the completion of surgery. It also has less risks of future infection or exposure than a Medpor ear. A clip-on osseointegrated prosthesis requires much more long-term maintenance in terms of keeping the studs clean, and there can also be problems getting the ear prosthesis to have solid fixation to the head. It is important to remember that if an osseointegrated prosthetic reconstruction is performed it is not possible to have an autogenous reconstruction later. On the other hand a prosthetic reconstruction is possible after a failed autogenous reconstruction.

When is the surgery best performed?

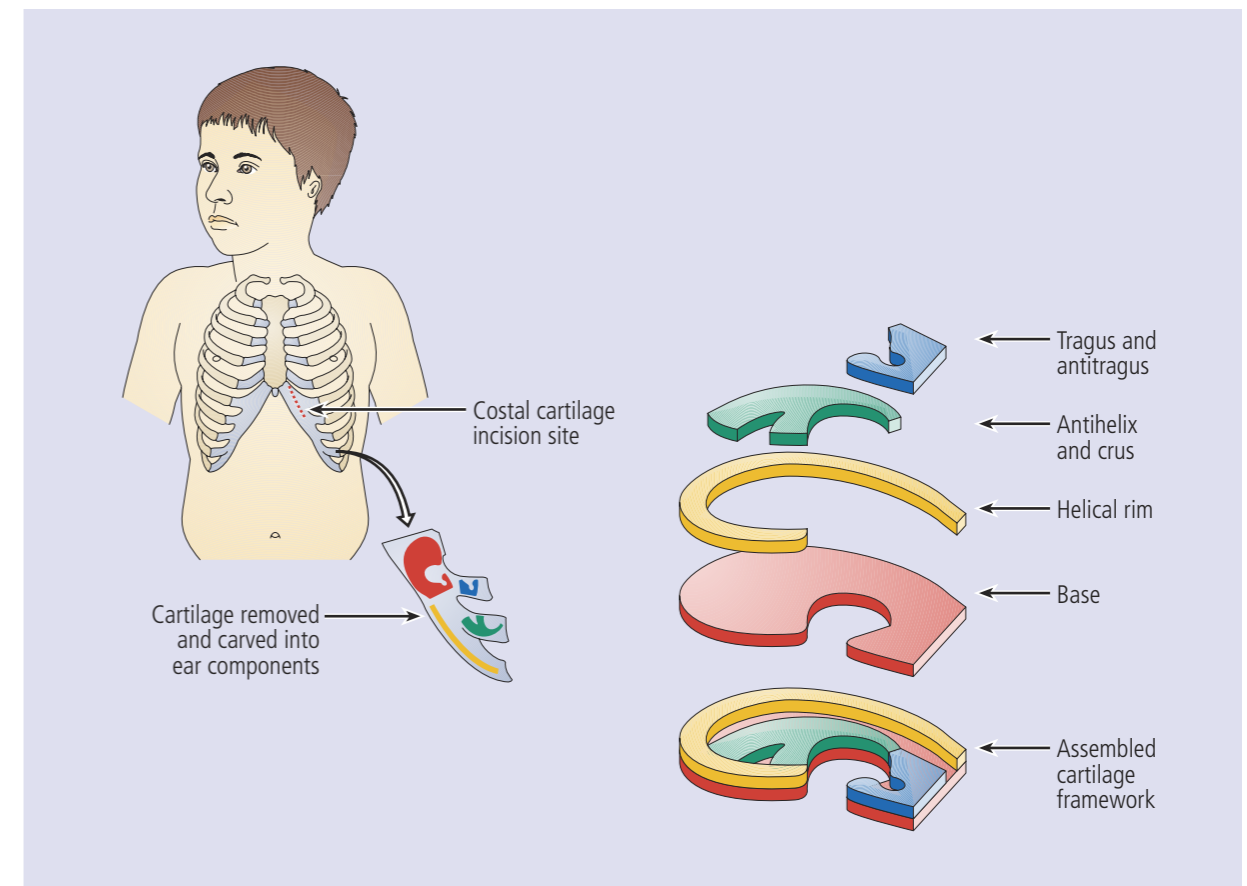
Ear reconstruction can be performed any time from around the age of six years, but is often deferred until the child requests surgery (8–10 years of age). At this time the rib cartilage is also large and strong enough to be carved properly into an ear. Some children are not concerned about their ear deformity and never request a reconstruction, so it is important that your child is involved in any decision for surgery.

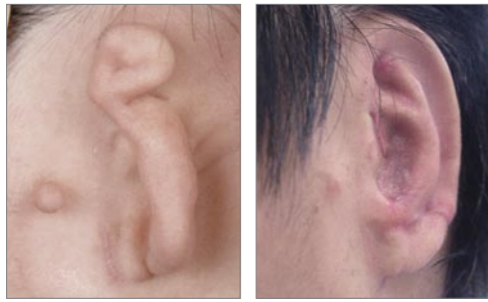Surgery for microtia

Stage 1 – Autogenous reconstruction

Your child will usually be admitted to hospital on the day of the surgery. The procedure is performed under a general anaesthetic and takes about four hours. A tracing will be made of the normal ear which will be used to design the framework for the reconstruction. Cartilage is harvested from the chest wall, through an incision which is around 10cm long. The cartilage from about three ribs is removed and carved into a framework which is designed to resemble the other ear. A drain will often be placed into the chest wound (Figure 2).

Figure 2. Removal of rib cartilage and assembly of new ear framework





Picture 4.
Typical microtia

Picture 5.
After stage 1 surgery

Depending on the ear remnants present on the microtic side, some of the parts may be used to make up some of the new ear, usually the lobule. Most of the abnormal ear cartilage is removed, and a skin pocket is formed, into which the cartilage framework is placed. A suction drain is used to encourage the skin to redrape over the framework, and the skin is closed.

The suction drain will be watched closely over the first few days, in order to ensure the skin sucks into all the crevices of the cartilage. The drain is removed after four days.

Pictures 4 and 5 show a typical microtia before and after stage 1 of the operation.

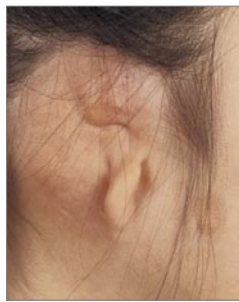Stage 2 – Autogenous reconstruction

The second stage of the ear reconstruction, which involves elevation of the created ear from the side of the head, is performed several months after the first stage.

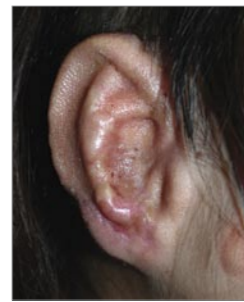An incision is made around the back of the new ear, and the ear is lifted up from the side of the head. Some cartilage from the first operation, which has been stored in the chest scar, is placed under the ear to help to hold it out from the head. The new groove behind the ear is covered with some tissue from under the scalp and then covered with a skin graft to line the new groove with skin (Figure 3). A drain is placed in the scalp, and dressings are put on.

The hospital stay after the second operation is usually shorter (often only overnight).

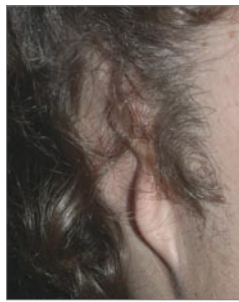Pictures 6 to 11 show a typical microtia from the beginning until completion of surgery (stages 1 and 2).



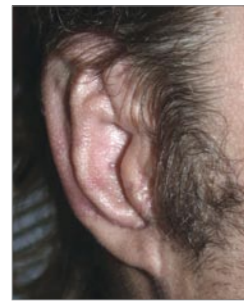Picture 6.
Microtia before surgery



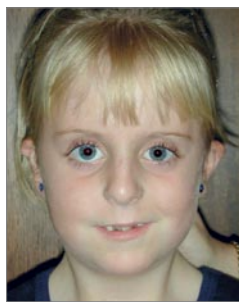Picture 7.
After stage 2 surgery



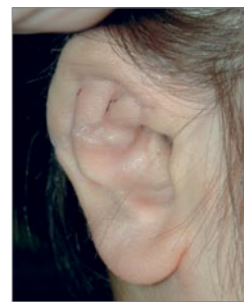Picture 8.
Microtia before surgery



Picture 9.
After stage 2 surgery



Picture 10.
Completed reconstruction



Picture 11.
Completed reconstruction

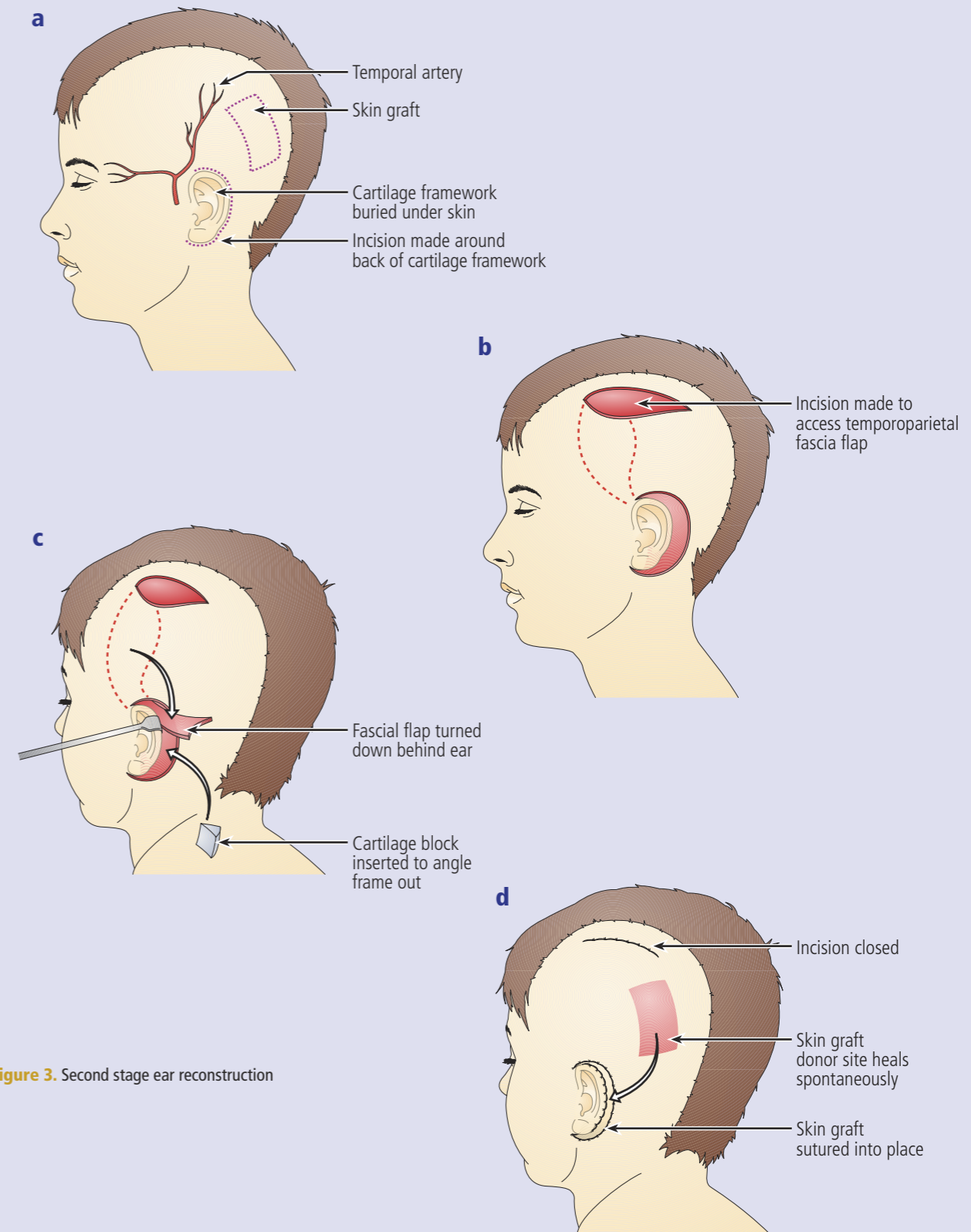
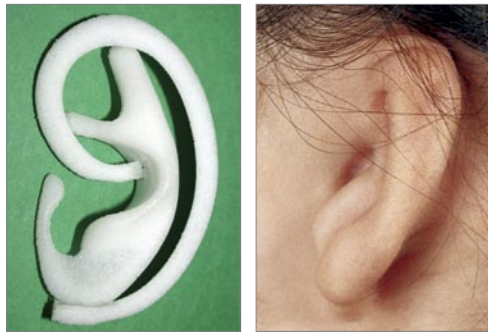

Figure 3. Second stage ear reconstruction



Picture 12. Medpor polyethylene implant and pre-operative ear

Medpor reconstruction

Instead of using rib cartilage to make the ear framework, an artificial framework made of porous polyethylene (Medpor) can be used. This is covered by the patient's own skin and a flap of tissue taken from the scalp. Skin grafts are also used, but a projecting ear can be made after one operation. Good results can be achieved but a second operation to add details to the ear will be needed and the framework may not be as resistant to infection or trauma as a rib reconstruction. Pictures 12 and 13 illustrate an example of Medpor reconstruction.

Other surgery

Sometimes a third procedure is necessary to trim off some excess skin from the ear, or to perform some minor adjustments to the ear, in order to obtain the best possible final result.

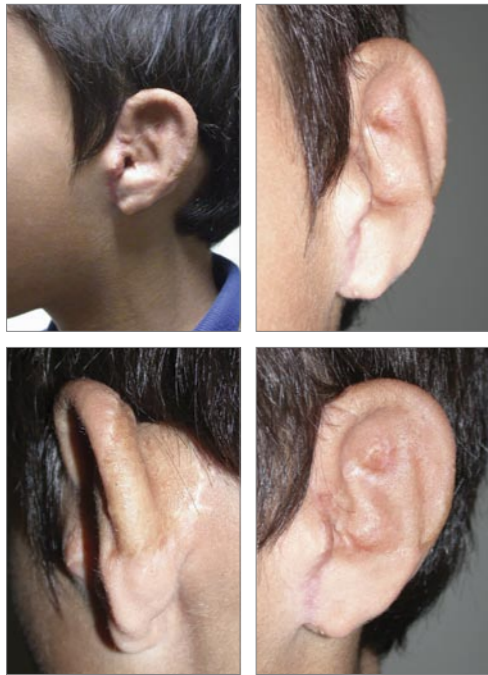
Surgery may be performed on the other ear to help obtain better final symmetry.

Laser hair removal is sometimes done to remove excess hair on the ear, or to improve the hairline before placing the ear in position.

Reconstruction of the hearing

Surgery to reconstruct a new ear canal and eardrum may be attempted in cases where the inner ear is normal, the middle ear is properly aerated and the overall structure of the skull around the ear is adequate to allow room for the new ear canal. A CT scan is performed to demonstrate these anatomical factors.

If it is possible, then this is usually done as a separate procedure by the ENT surgeons, after the reconstruction of the external ear is complete. This involves creating an opening down to the middle ear, making an ear drum, and then lining this tunnel with a skin graft.



Picture 13. Post-operative views of a case performed with Dr. John Reinisch showing results of a Medpor reconstruction after two procedures

In cases where the structure (anatomy) of the ear is not suitable for reconstruction of the ear canal and hearing, an osseointegrated (fixed to the bone) screw fixture can be used to attach a hearing aid directly to the skull behind the ear. This allows more effective sound transmission to the inner ear. Placement of the screw fixture requires a relatively minor surgical procedure.

Other ear conditions

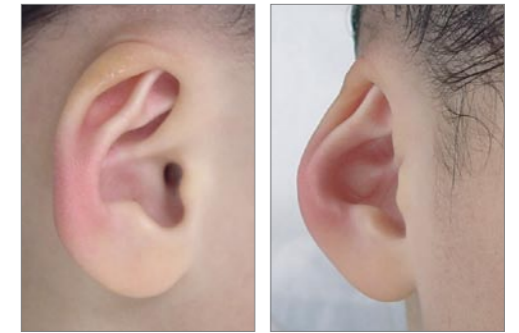Cryptotia

Cryptotia literally means "hidden ear". In this condition the upper part of the ear is buried beneath the skin of the scalp. Usually the cartilage is normal. Reconstruction involves lifting the ear out from under the skin, creating a groove behind the upper ear and using flaps of the surrounding skin to cover the ear cartilage. This is usually done as a day procedure in a single stage. Pictures 14–17 show the treatment of cryptotia.

Lop ear

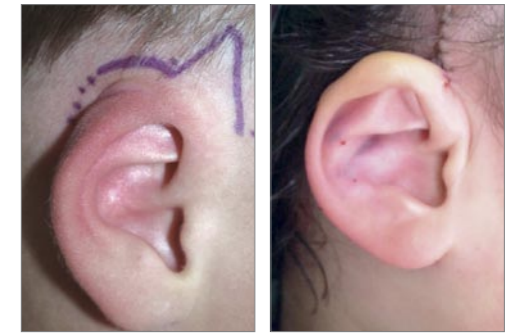A lop ear is one in which the upper part of the ear is bent over. There is often a relative shortage of skin and the cartilage framework may also be smaller than the other side. Surgery involves correction of the cartilage using either the cartilage already in the ear, or sometimes a cartilage graft from the other ear. Skin cover involves using local skin flaps. When severe, this condition occasionally requires correction with the use of a rib graft, similar to the procedure for microtia.

Pictures 18 and 19 show a lop ear before and after treatment.



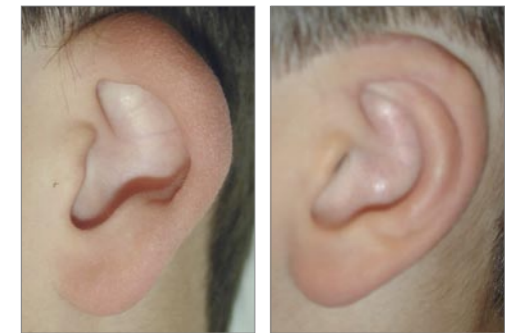
Picture 14. Cryptotia (side view)

Picture 15. Cryptotia (front view)



Picture 16. Markings for skin flap

Picture 17. Flap sutured in place



Picture 18. Lop ear

Picture 19. Lop ear after surgical correction



This publication is provided
with the compliments of the

**Mark and Chapter
Freemasons of Victoria**

Freemasonry is an ancient and respectable institution, embracing individuals of every nation, of every faith and every condition of life. It can be defined as a benevolent, charitable, educational and ethical society. It strives to teach every moral and social virtue and exhorts its membership to practice the universal principles of brotherly love, relief and truth.

**Masonic Centre of Victoria
300 Albert Street
East Melbourne Victoria
Australia 3002
Telephone + 61 3 9419 8687**