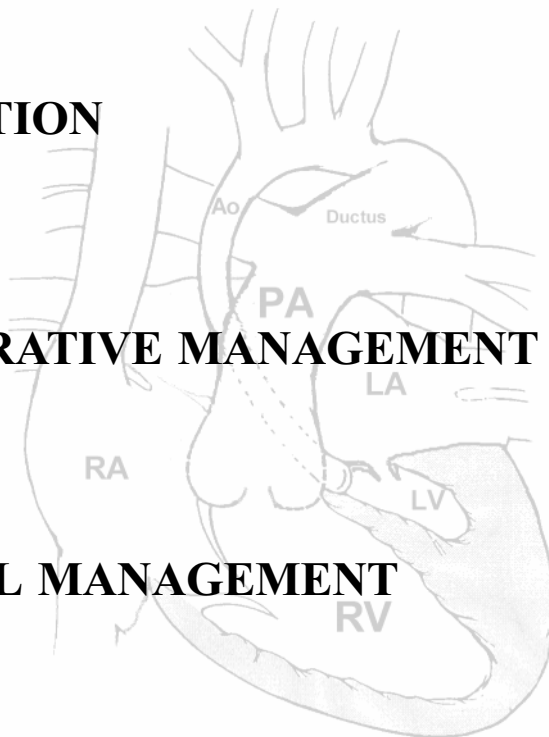


HYPOPLASTIC LEFT HEART SYNDROME

➤ **DESCRIPTION**

➤ **PRE-OPERATIVE MANAGEMENT**

➤ **SURGICAL MANAGEMENT**



DESCRIPTION.

➤ WHAT DOES HLHS CONSIST OF?

It is a severe heart defect in which the left side of the heart is poorly formed, and the left ventricle, mitral valve and aorta are all small/hypoplastic.

"Typical features include severe hypoplasia or atresia of the mitral and aortic valves and a severely underdeveloped left ventricle. The ascending aorta is markedly hypoplastic with a discrete coarctation in the periductal region. A large ductus arteriosus is present with an enlarged and dilated pulmonary valve and main pulmonary artery. The right ventricle is dilated and hypertrophied."

(Chang, A.C., Hanley, F.L., Wernovsky, G., Wessel, D.L. (Ed.), (1998) Paediatric Cardiac Intensive Care. Baltimore: Williams and Co.)

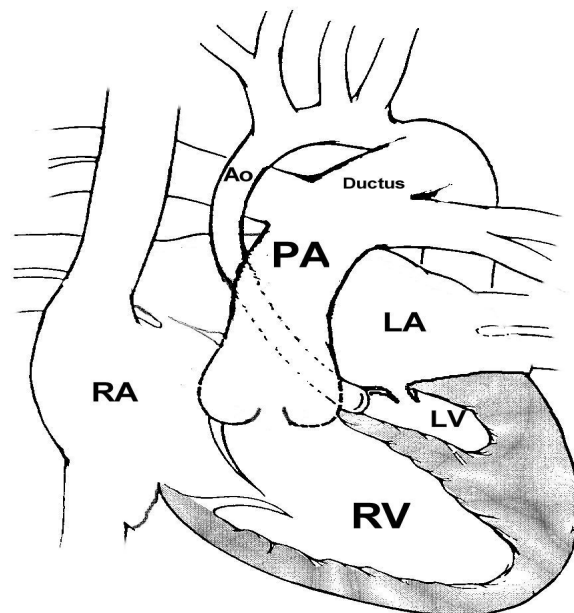
Glossary:

Hypoplasia - small or underdeveloped

Atresia - complete obstruction

Coarctation - narrowed area

Hypertrophied - thickened or enlarged area



➤ WHAT EFFECT DOES THIS HAVE ON THE HEART?

There is a severe obstruction to systemic blood flow, which must rely upon blood flow through a patent ductus arteriosus. Pulmonary venous return may also be obstructed as the left heart is small and the Foramen Ovale may restrict shunting between the left and right atria.

PREOPERATIVE MANAGEMENT.

Patients with an oxygen saturation of more than 90% may have decreased oxygen supply to tissues yet have a high arterial oxygen saturation. This is related to high flow to the pulmonary circulation with reduced systemic blood flow, which leads to decreased tissue perfusion and metabolic acidosis.

Initially:

- Use of Prostaglandin E1 to keep the ductus arteriosus open in the neonate.
- Use of inotropic drugs, such as dopamine or dobutamine, to maximize blood flow through the patent ductus arteriosus. This increases blood pressure and systemic blood flow.

Then:

- Supplemental nitrogen can induce alveolar hypoxia to help elevate PVR, as can intubation (permissive hypoventilation which elevates CO₂ which increases PVR), and a maintained haematocrit (increased viscosity can increase PVR). Increased PVR will tend to prevent the pulmonary flow from increasing to very high levels and will also improve blood pressure and flow in the systemic circulation.

Glossary:

Pulmonary vascular resistance - resistance in pulmonary vascular bed.

Systemic vascular resistance - resistance in the systemic circulation.

SURGICAL MANAGEMENT.

➤ GOALS OF SURGICAL MANAGEMENT.

- unobstructed systemic blood flow
- limited pulmonary blood flow (decreases pulmonary hypertension) and unobstructed pulmonary venous return (also decreases pulmonary hypertension)
- avoidance of dysrhythmias
- minimize pulmonary artery distortion

➤ SURGICAL PROCEDURES PERFORMED AND THE SEQUENCE REQUIRED.

1. STAGE 1 NORWOOD.

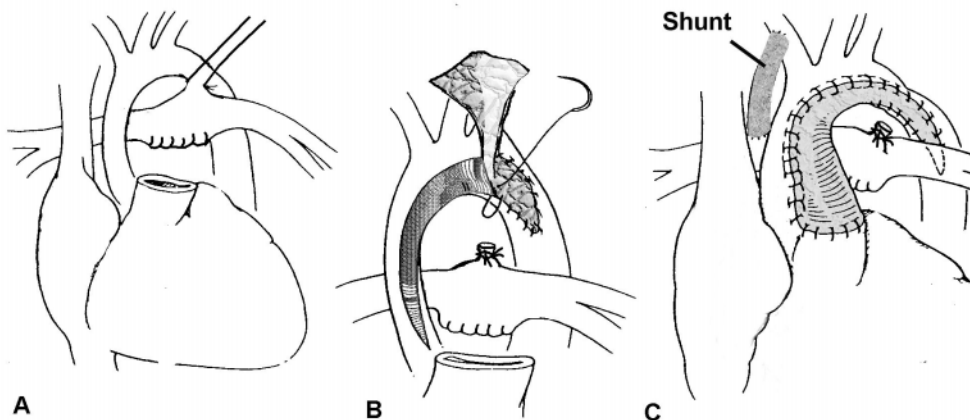
- to establish reliable, unobstructed outflow to the systemic circulation and to balance systemic and pulmonary circulations.
- apply the following descriptions to the diagram below:
 - A. The ductus arteriosus is ligated and divided and the central and branch pulmonary arteries are detached from the main pulmonary artery
 - B. The hypoplastic aorta is then opened and a patch augmented to this region.
 - C. The augmented aorta is then attached to the cardiac end of the main pulmonary artery stump.
 - an atrial septectomy, to ensure unobstructed pulmonary venous flow, is performed, as is a right-sided Blalock-Taussig shunt which ensures blood supply to the pulmonary circulation (see following diagrams).

Glossary:

Ligated - tying off.

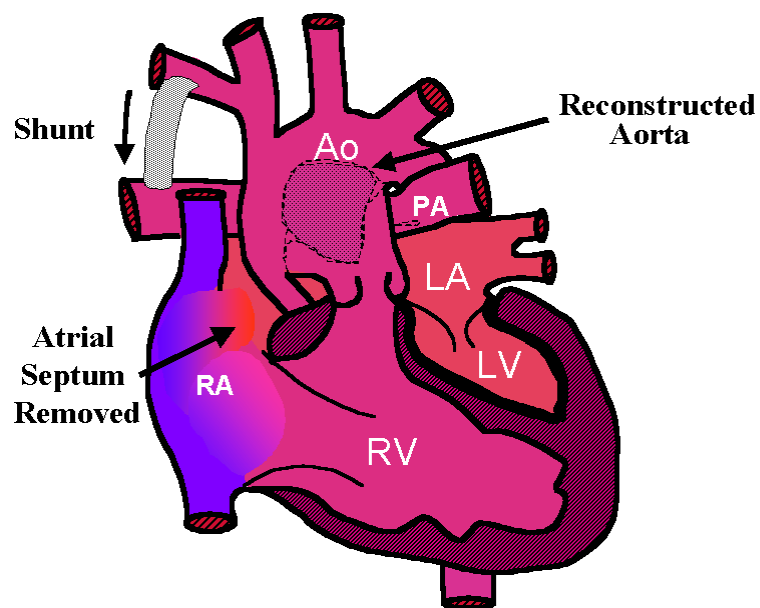
Augmented - enlarged

Septectomy - septum between left and right atriums removed



NORWOOD PROCEDURE

AS PERFORMED FOR HYPOPLASTIC LEFT HEART SYNDROME.



BIDIRECTIONAL CAVO-PULMONARY SHUNT / BIDIRECTIONAL GLEN.

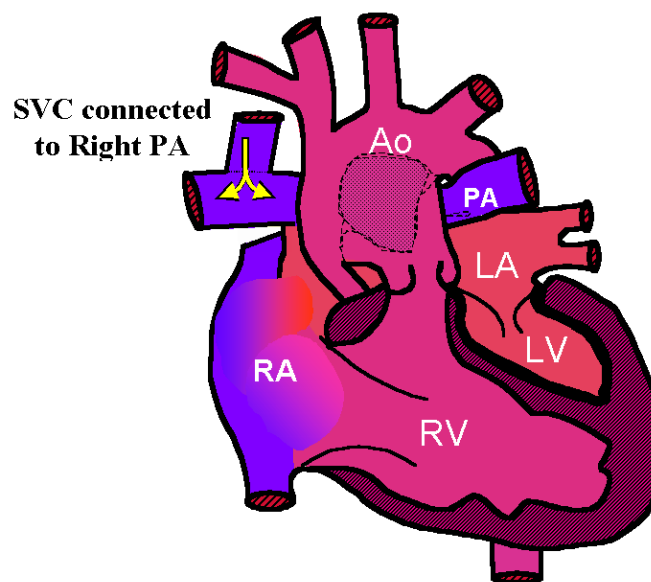
- generally performed on infants between 3 to 6 months of age.
- this decreases the work of the right ventricle by decreasing the 'volume load' - (the volume of blood that the heart needs to pump with each beat).
- involves transecting the superior vena cava at the right pulmonary artery level and anastomosing the cephalad portion of it to the proximal right pulmonary artery. The cardiac end of the superior vena cava is oversown

Glossary:

Transecting - sever or cut across.

Anastomosing - surgical joining

Cephalad - cranial



3.

FONTAN.

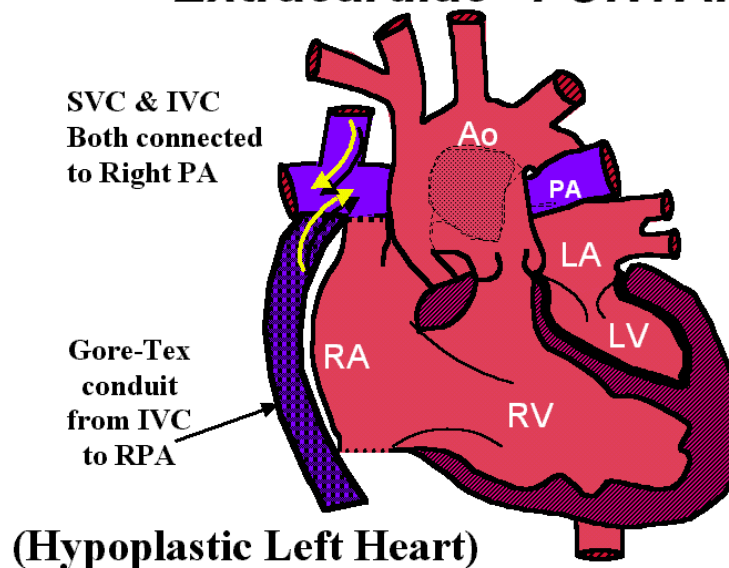
- this completes the reconstructive surgery required and available for the HLHS patient
- the superior and inferior vena cava are connected to the lung arteries allowing blood to flow directly to the lung circulation, bypassing the right ventricle.
- this optimizes cardiac output.

There are two types of Fontan procedures:

A. EXTRACARDIAC FONTAN

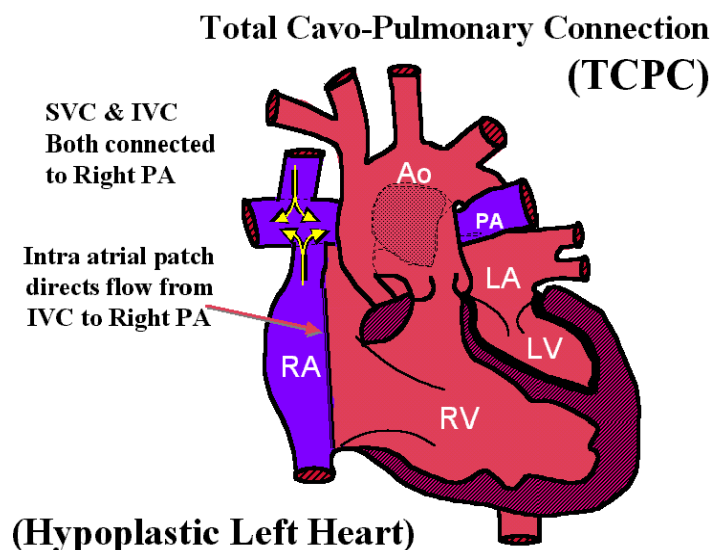
- most commonly performed Fontan procedure at present as no suturing needs to take place within the right atrium, and right atrium pressures are minimized.

“Extracardiac” FONTAN



B. INTRACARDIAC FONTAN / TOTAL CAVO-PULMONARY CONNECTION.

- less commonly used due to the suturing required. Such suturing can cause arrhythmias. This also leads to increased pressure in the part of the right atrium that is used to carry the IVC blood to the Pulmonary Arteries.



BIBLIOGRAPHY:

Curley, M., Bloedel Smith, J., Moloney-Harmon, P., (1996). Critical care nursing of infants and children. Philadelphia: W.B. Saunders Company.

Glanze, W., Anderson, K., Anderson, L. (Ed.). (1990). Mosby's medical, nursing and allied health dictionary. St Louis: The C.V. Mosby Company.

Nichols, S., Steven, J., Jobes, A. (1995). Hypoplastic Left Heart Syndrome. In Nichols GD et al, (Ed.), Critical heart disease in infants and children. St Louis: Mosby.